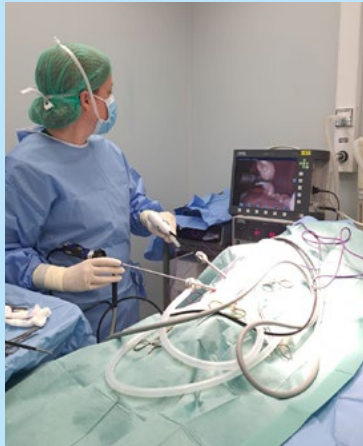

ProVetSurg – Your local visiting surgical and imaging service • For a full procedure list visit [provetsurg.co.uk](http://provetsurg.co.uk)

## Laparoscopy has launched!

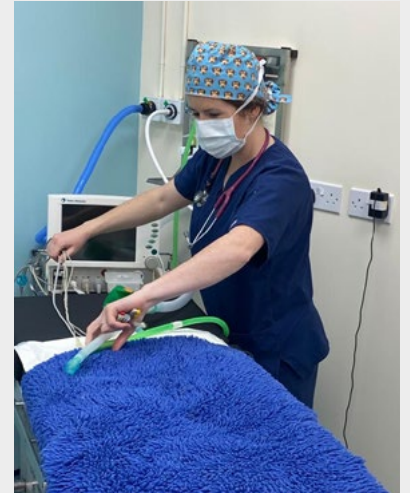
We are excited to report that our laparoscopy service is now up and running and our laparoscopic spay clinics led by soft tissue surgeon Ana, have been very popular. We have also taken bookings for laparoscopic retrieval of cryptorchid testes and biopsy of abdominal viscera. If you would like more information about this progressive service please email [info@provetsurg.co.uk](mailto:info@provetsurg.co.uk)



## Celebrating our nursing team

Did you know that when you book a surgery or ultrasound scan we can bring a nurse with us to help ease the pressure of busy clinic life on your team? Our nursing team has been especially busy with clinical case support over the last few months and we are very pleased to be able to support our client practices with this service. Please just let us know at the time of booking a case in if you would like a nurse to accompany our surgeons to help with:

- Preparing for and monitoring anaesthetics
- Supporting surgeons by scrubbing in to surgeries
- Assisting with surgical set up
- Providing support and knowledge to practice teams
- All with a cheerful smile!



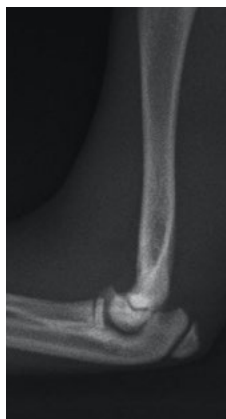## Case study: Distal humeral physeal fracture

Boo is a 16 week old kitten who had an unlucky fall whilst playing with his housemate at home and presented with an unusual elbow fracture involving the distal humeral physis. His fracture was repaired with tiny 0.6mm arthrodesis wires during a very delicate surgery to allow continued growth at the physis. Early stabilisation and perfect anatomical reduction was very important to allow a good functional outcome for this fracture. We are pleased to report that following 4 weeks of crate rest Boo has made an excellent recovery.

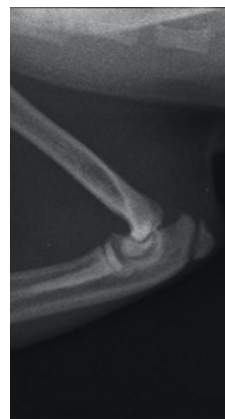Boo and his friend



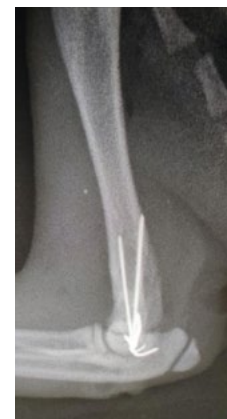Neutral mediolateral radiograph



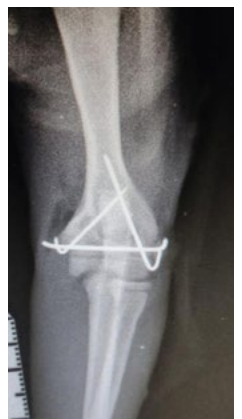Flexed mediolateral radiograph



Post operative mediolateral radiograph



Post operative craniocaudal radiograph



# Focus on: physeal fractures

Physeal, or Salter Harris fractures are fractures that occur in skeletally immature patients and involve the growth plates or physes. These fractures can occur with minimal or no trauma, and patients can present following vigorous play, jumping or running.

There are several different configurations of Salter Harris fractures. One of the most common that we see is a tibial crest avulsion fracture in young, well muscled breeds such as French Bulldogs and Staffordshire Bull Terriers.

Tips for diagnosing physeal fractures

- Always take radiographs if there is soft tissue swelling to a physeal region
- If it isn't clear whether there is a fracture, take the same view of the contralateral limb
- If you think there is minimal displacement, take a stressed radiographic view to demonstrate instability
- If lameness is ongoing re-radiograph after 3-5 days to check for displacement of a previously undisplaced fracture

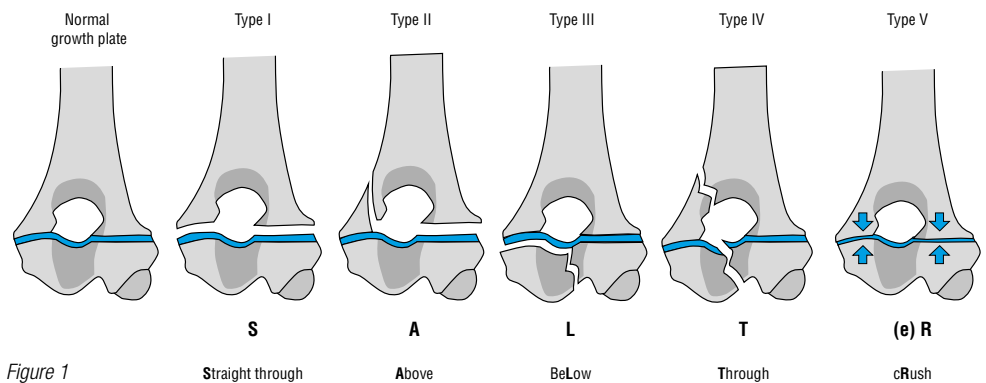


Figure 1

Physeal fractures require prompt surgical stabilisation and are normally managed with smooth arthrodesis wire fixation to preserve whatever growing potential remains in the physis.

We will often recommend removal of implants following radiographic confirmation of healing, particularly in cases of tibial crest avulsion fractures.

Owners should always be warned of the potential for limb angulation as a patient continues to grow following a physeal fracture, this is because the physis can be damaged asymmetrically and one side can continue to grow whilst the other ceases to grow.

## Meet our team

We are so lucky to have such a friendly, approachable and helpful team at ProVetSurg bringing a wealth of knowledge between us. This scoop, we all wanted to share with you why we love working at ProVetSurg

### Dr Nicci Meadows – Surgeon

BVetMed CertAVP GSAS MRCVS


I love meeting all of the clients and helping their pets, but most of all I enjoy working with host practice team members and sharing knowledge and top tips with them, and in return seeing lots of different ways in which practices work and picking up new ideas along the way.



### Dr Heidi Burkinshaw – Surgeon

BSc(Hons) BVetMed PgC(SAS) MRCVS

I really enjoy being part of the practice team each time I visit and it's great to catch up on the latest ideas in clinic whilst we are in each practice



### Dr Chris Nikolaou – Surgeon

DVM CertAVP GSAS MRCVS

I love feeling like I am part of multiple teams who all have the same goal: to provide the best service possible to families and their pets.



### Dr Ivan Filipovic – Surgeon

DVM, PgC (SAS)

I enjoy seeing confidence build in our host practice teams, whether nurses, vets, or students, when a procedure previously not available to the practice becomes more routine. I also love a good pre-op cuddle with the patients!



### Dr Ana Murta – Surgeon

MSc, PgC SAS, MRCVS

What I like the most about this job is meeting the staff and sharing my love for soft tissue and minimal invasive surgery with a lot of different people. It is great to be able to offer a service like laparoscopy and practices don't seem to mind the space I take up with all of my kit-suitcases!!



### Dr Ana Afonso – Surgeon

DVM GPCert(DI) PgC(DI) MRCVS

I love helping the primary care vet team with the imaging of a case knowing it will directly help the patient and the owners. Because I work "backstage" I feel like the Mary Poppins of the ultrasound world - I show up whenever you need me and then go on to help another practice!



### Dr Dan Troup – Registrar Surgeon

BSc (Hons) BVSc MRCVS


I love visiting all of the practices and reconnecting with many colleagues I have worked with in the South over the years.



### Bev Morgan – Surgical Nurse

RVN


I love working with our fantastic team of surgeons and nurses dedicated to going the extra mile to provide excellent patient care and I really enjoy helping other teams in practice to ensure cases run smoothly.



### Lauren Flack – Surgical Nurse

RVN CertVNECC

It is so rewarding to travel between practice, experiencing and sharing so many nursing tips and tricks passed between teams, allowing everyone's skills to progress in turn giving the best care to all of our patients!



### Hannah Stacey – Physiotherapy adviser

PG Dip Veterinary Physiotherapy, BSc (Hons)

ProVetSurg are fantastic to work alongside, they are approachable, willing to work with a wider multidisciplinary team and always looking at what is the best treatment for each individual patient/client



We are on Instagram, LinkedIn and Facebook - catch the latest news on our social pages

